

THE IMPORTANCE OF FOLLOW-UP:
A CASE OF A TWENTY SEVEN YEAR OLD FRACTURE

By Dr. Robert Ben Mitchell, D.O.

Member - American Academy of Pain Management

Affiliations: none

June 21, 2002

ABSTRACT:

Follow-up is the art of coordinating continuity between what you do for a patient today and what you will need to do for them tomorrow (3, 4). As such, it is the back-bone of integrated medical care for all patients and should be routinely performed in all health care situations and settings. Due to its routine nature, however, the importance of follow-up can often be taken for granted. This case study describes a patient who voluntarily delayed medical follow-up for twenty seven years, only to discover he had been walking on an incompletely healed right leg fracture all that time. It will hopefully serve as an object lesson to remind doctors and patients alike about the importance of prompt follow-up care.

KEY WORDS:

1. Follow-up
2. Chronic Pain Management Program [CPMP]
3. Tibia-fibula fracture
4. Valgus deformity
5. Open reduction, internal fixation [ORIF]
6. Hepatitis C

ARTICLE:

As the medical director of a Chronic Pain Management Program (CPMP), I focus my practice of medicine upon chronic pain: pain lasting longer than the usual course of an acute illness or injury, or ongoing pain associated with chronic illness (1). Chronic pain, like all pain, is amorphous. There are no diagnostic studies which can visibly demonstrate it, and there are no laboratory or clinical tests by which to objectively quantify it. However, it is critical to remember that though it is invisible, often a physically tangible process can be identified as the cause of chronic pain.

Each CPMP has its own unique manner by which it evaluates and treats chronic pain. Some employ an in-house, multi-disciplinary approach with a wide spectrum of services available under one roof (2). Others focus specifically on the medication aspect of chronic pain management, sending the patient “out” for follow-up on all other needed services (physical therapy, laboratory work, counseling, diagnostic studies, etc.). Our CPMP is of the latter type. Patients are seen on a fee-for-service basis at our facility, and they return for follow-up visits with us at least once every two weeks while undergoing treatment. Only pain medication consultation services are provided, and we require patients to make their own arrangements for their primary and specialty medical care, as well as any follow-ups which we advise. It is always critical to remember that follow-up is the key to comprehensive care for all patients, regardless of the treatment philosophy employed.

Follow-up is the art of coordinating continuity between what you do for a patient today and what you will need to do for them tomorrow (3, 4). Physicians perform follow-up every time they

order labs, x-rays, surgical consults and other services designed to advocate and protect the well being of their patients. Yet, as the act of follow-up becomes part of our daily routine, it can also be taken for granted. We may at times forget that although we see many normal reports on our desks, that it is the one or two abnormal values for which we must constantly be on the look-out. The following case study demonstrates the importance of follow-up and why it should never be taken for granted by either doctors or their patients.

A 44 year old male without medical insurance coverage presented to my CPMP by self-referral in early June of 2001, with a chief complaint of right, mid calf pain predominantly after work and at night. He was a project manager in a job which required considerable travel to, and walking around construction sites. He stated that on work days he had little pain during the morning and early afternoon, but when he got home his calf was often quite painful making sleep difficult. These symptoms originated and progressed since 1973 when he was injured in a car accident, suffering a double-compound, right tibia-fibula fracture. The leg was originally treated without open reduction, internal fixation (ORIF), casted for six months, then re-broken and reset again without ORIF, followed by casting for another 8 months. The patient had no further follow-up for the leg after the second cast was removed, and he assumed that it had healed. However, during the next 27 years he had intermittent episodes, lasting a few weeks to a few months, of mild to moderate pain in the right calf region. It was not until mid 2001 that these symptoms became significant enough for him to present to a CPMP for consultation and pain management.

At his initial presentation he denied any other significant past medical history or the current use of any prescription medications, stating he was only taking over the counter NSAID's for pain control. Examination revealed a well spoken, middle aged male who appeared his stated age, height of five feet and ten inches, weighing 180 pounds. He required no assistance during transfer or ambulation, walked without any discernible antalgic gait, had full range of motion at the right knee and ankle, and displayed no significant asymmetry in, or tenderness to palpation of the right leg.

When questioned about prior prescription medication he had used for this problem, the patient stated that Dilaudid, 2 mg, once daily produced the best results. He also claimed that his current symptoms were significantly worse than when he had previously used Dilaudid. Based upon the above, he was prescribed Dilaudid, 2 mg, one to two every day if needed (PRN). This initial regimen has the equivalent analgesic strength of taking one to two Tylenol #3's a day (5), but had the advantage of containing no acetaminophen which can cause liver damage with chronic use (6). As the patient's prior right calf symptoms had been episodic and his apparent need for medication was minimal, a second visit was set for two weeks to determine if ongoing evaluation and treatment would be necessary. Lab work and other follow-up were deferred until this second appointment.

At his second visit in late June of 2001, the patient described insufficient pain relief using the medication dosage as prescribed, but still claimed to only need the medication after work and just before bedtime. With further evaluation, his case warranted continuing care and additional follow-up studies. He was instructed to get specific lab work done (CBC, basic blood chemistry, hepatic function tests, and urinalysis) and to arrange for an orthopaedic assessment of his right leg, as no

current records were available. The patient agreed to do the labs immediately, but requested to defer the orthopaedic exam for four weeks so he could first arrange for medical insurance coverage. This was agreed to and his regimen was changed to Dilaudid, 4 mg, one after work PRN and one before bedtime PRN.

Treatment continued throughout the remainder of 2001 with the above adjusted regimen. The patient promptly appeared every two weeks for his regular visits, and at each visit I made repeated requests for him to obtain his labs and orthopaedic assessment. However, though he acquired health insurance shortly after his second appointment, the patient continually procrastinated and it would take until early December for him to obtain his lab work. He never arranged an orthopaedic visit during 2001.

The December lab results indicated anemia (Hg 10.1, Hct 31.8), neutropenia (WBC 2.7), thrombocytopenia (platelets 80), and elevated liver function tests (AST 47, ALT 50). The patient was immediately referred for hematologic follow-up where he was diagnosed with stage two, recurrent hepatitis C. He denied any knowledge of previous exposures to, or episodes of acute hepatitis C, and stated that the hematologist told him the current illness was likely activated by his recent increase of weight to nearly 200 pounds during the latter half of 2001. His health markedly decreased in early 2002, because of the hepatitis, and it would not be until early May that he would lose the weight gained the previous year, thus sending his illness back into remission. However, by June 1st of 2002, due to his six month preoccupation with the hepatitis, the patient had still not followed-up on an orthopaedic assessment.

On June 14th, 2002, a year after he was first seen, this patient came to his regular two week visit with an x-ray of his right lower leg, obtained several days earlier during a visit to an orthopaedic surgeon who indicated a need for surgery. On review of this x-ray, the patient had a complete, nonunion, mid-fibular fracture, and a mid-tibial valgus deformity of 15 degrees (Figure 1). The fractured fibular ends were offset laterally by 2 mm, with the ends migrating 14 mm past one another (Figure 2). A small boney callous is evident at the distal tip of the proximal fibular half (Figure 2 - label A), with the free ends of both halves otherwise smooth and rounded. Maximal tibial valgus deformity appears medially just below mid shaft (Figure 3 - label A), with reactive bone changes indicating probable stress fractures at the same level on the lateral aspect of the bone (Figure 3 - label B). Corresponding degenerative changes are seen at both the knee (Figure 4) and ankle (Figure 5).

From this x-ray and the patient's past medical history, it appears that the treatment of his compound fractures in 1973 was probably successful for the tibia, but not as it relates to the fibula. Though the small boney callous (Figure 2 - label A) suggests initial healing, the now disjointed fibular ends likely re-separated shortly after the final cast was removed fourteen months from the original injury. During the next twenty seven years, without fibular support, the weight bearing tibia developed a progressive mid-shaft valgus angulation (Figures 1 and 3), with corresponding degenerative changes in the joints above and below the deformation (Figures 4 and 5). The smooth roundness of the free fibular ends indicates that this process had been ongoing for an extended period of time (Figure 2). Also, the stress fractures on the lateral tibial aspect directly across from the point of maximal valgus deformity (Figure 3 - labels A and B) hint at the impending re-fracturing of the weight bearing bone had the patient further delayed orthopaedic care. These findings correlate with

the fact that his pain medication use tripled during the first half of 2002, most likely due to continued stress on the tibia. In my opinion, his chronic pain was due to the fibular instability (Figures 1 and 2), the increasing changes in tibial angulation (Figures 1 and 3), and the degeneration of the joints above and below these deformities (Figures 4 and 5).

CONCLUSION:

With continued remission of his hepatitis C and aggressive orthopaedic intervention, this patient's prognosis is guarded at this time. While corrective orthopaedic procedures such as ORIF present their own unique challenges to patient rehabilitation, such acute care should resolve his chronic pain situation. In the meantime, he and I have learned a valuable lesson: do not delay follow-ups for any reason. In terms of both his hepatitis and right leg, he was long overdue in obtaining the recommended follow-ups, and had he waited much longer, the results could have been catastrophic. Hopefully, this case will have a happy ending. For now, I have permanently placed his x-ray on display in my consultation room as an object lesson for both my patients and myself. Next to it I have placed a sign that reads, "YOU NEVER KNOW!" That is, unless you get your follow-up.

DEDICATION:

This paper is dedicated to Dr. Raymond Failer, D.O., who provided invaluable critiques of this and prior papers, Robert Novigrod, R.P.H., whose insights into pharmacology make my practice possible, and Dr. Paul Glassman, D.O., who taught me everything I know about medicine.

REFERENCES:

1. Texidor MS. The nonpharmacological management of chronic pain via the interdisciplinary approach. In: Weiner RS, editor. Pain management, a practical guide for clinicians, 5th ed. Boca Raton: St. Lucie Press, 1998; 123-135.
2. Shealy CN, Cady RK. Multidisciplinary pain clinics. In: Weiner RS, editor. Pain management, a practical guide for clinicians, 5th ed. Boca Raton: St. Lucie Press, 1998; 35-44.
3. McGrath V. The importance of follow-up: why is it my responsibility? *J Med Pract Manage* 2001; 17(2): 90-92.
4. Guglielmo WJ. Follow-up care: nuts, bolts, carrots and sticks. *Med Econ* 2001; 78(18): 30, 35-36.
5. American Pain Society. Principles of analgesic use in the treatment of acute pain and cancer pain, 4th ed. Glenview: American Pain Society, 1999; 6-7, 8, 14-15.
6. Supernaw RB. Pharmacotherapeutic management of selected pain phenomena. In: Weiner RS, editor. Pain management, a practical guide for clinicians, 5th ed. Boca Raton: St. Lucie Press, 1998; 137-150.

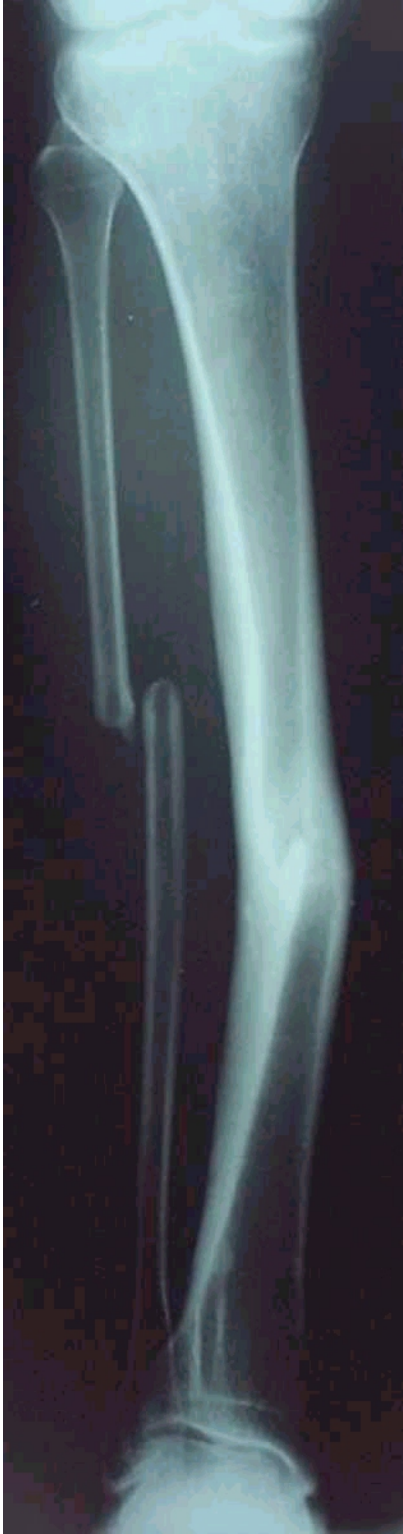

Figure 1: Right leg from knee to ankle.

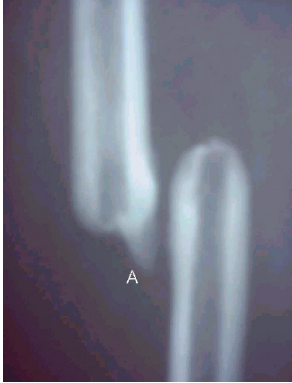

Figure 2: Disjuncted right fibular ends with small bony callous (label A).

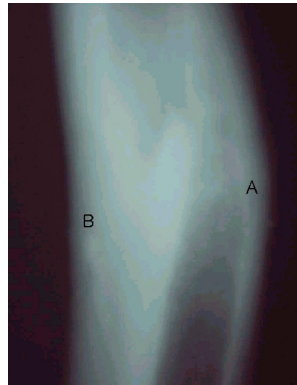


Figure 3: Maximal right tibia valgus deformity (label A) with corresponding region of probable stress fractures (label B).

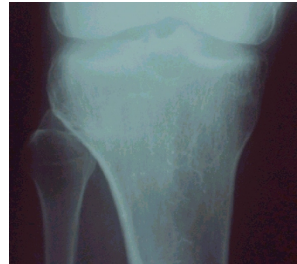

Figure 4: Corresponding degenerative changes at the right knee.

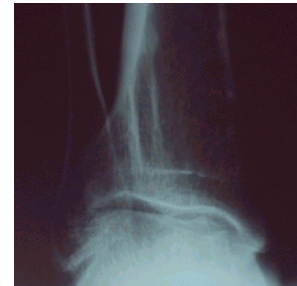

Figure 5: Corresponding degenerative changes at the right ankle.